



## **Digestive system, femur and tibia bone characteristics of Dworka and Pekin ducks**

**Karol Włodarczyk<sup>1</sup>, Dariusz Kokoszyński<sup>2\*</sup>,  
Rafał Zwierzyński<sup>3</sup>, Marcin Wegner<sup>2</sup>, Małgorzata Grabowicz<sup>2</sup>,  
Dorota Banaszewska<sup>4</sup>, Mohamed Saleh<sup>5</sup>**

<sup>1</sup> Institute of Agricultural and Food Biotechnology – State Research Institute,  
Rakowiecka 36, 02-532 Warsaw, Poland

<sup>2</sup> Department of Animal Breeding and Nutrition, Bydgoszcz University of Science and Technology,  
Mazowiecka 28, 85-084 Bydgoszcz, Poland

<sup>3</sup> Kołuda Wielka Experimental Station of the National Research Institute of Animal Production,  
Parkowa 1, 88-160 Kołuda Wielka, Poland

<sup>4</sup> Institute of Animal Science and Fisheries, Faculty of Agrobioengineering and Animal Husbandry,  
Siedlce University of Natural Sciences and Humanities, Prusa 14, 08-110 Siedlce, Poland

<sup>5</sup> Department of Poultry Production, Faculty of Agriculture, Sohag University,  
Nasser City, 82524, Sohag, Egypt

*(Accepted August 17, 2023)*

The aim of this study was to determine traits of the digestive system and femur and tibia bone of Dworka and Pekin ducks. A study was conducted on 24 Dworka duck (breeding strain D11) carcasses and 24 Pekin duck (conservative strain P9) carcasses, 12 male carcasses and 12 female carcasses from each strain. The lengths of the intestinal segments were tape measured. The diameters of the intestinal segments and leg bone dimensions were measured with an electronic calliper. The results obtained differed by genotype and sex for internal organ weights (Dworka male ducks in general had heavier organs), for the length of intestinal segments (Dworka male ducks had longer some intestinal segments), while for bones the results obtained were similar, regardless of genotype and sex. Dworka and Pekin ducks of both sexes differ in the weight of their some internal organs, the length and diameter of their intestinal segments and dimensions of their bones. This may be due to

---

\* Corresponding author: kokoszynski@gmail.com

different growth rates of selected ducks (D11 Dworka) and non-selected ducks (P9 Pekin).

**KEY WORDS:** Dworka / Pekin / digestive system / femur and tibia

The digestive system of birds develops proportionally depending on the species. As birds grow, the percentage of lean meat and skin with fat increases and the percentage of bone content decreases. Fast-growing birds are characterised by rapid growth of the digestive system [Wasilewski *et al.* 2015], which can result in stress on the immature skeleton, in turn potentially leading to various skeletal deformities and disorders [Cooper *et al.* 2008, Robison *et al.* 2015]. In a study by Konarkowski [2006] it was shown that in 7-day-old ducks the small intestine is 3.7 times heavier and 1.6 times longer than in twice lighter turkeys of the same age. Growth of the small intestine is relatively greatest early in the birds' lives, then it slows down with age [Wasilewski *et al.* 2015]. According to Watkins *et al.* [2004], the digestive system of Pekin ducks reaches morphological and functional maturity after 7 weeks of age. Duggan *et al.* [2015] showed that Pekin ducks (Cherry Valley commercial hybrid) produced for meat can reach a body weight of 2.5 kg within 5 weeks. The intestinal tract is a very important part of the body's defence system and the main site for digestion and absorption of nutrients from feed [Garro *et al.* 2018, Chen *et al.* 2021]. Ducks from conservative flocks (e.g. Danish Pekin - P8 strain, French Pekin - P9 strain, Polish Pekin - P33 strain) are more resistant to various diseases and adapt more easily to changing environmental and nutritional conditions; however, this negatively affects their meatiness and reproductivity [Książkiewicz 2012]. Bone growth is primarily influenced by nutrition; however, genetic conditions and production practices also have a significant impact. One of the most important trace elements required for bone formation in poultry is zinc. Deficiencies of this element affect the feeding behaviour of birds and inhibit mineralisation and bone formation [Wen *et al.* 2019, Zhang *et al.* 2020]. Another important mineral is calcium. Structural bone loss and the development of osteoporosis may be related to the source of calcium for eggshell formation, therefore it is very important to assess bone quality, especially for laying birds [Cui *et al.* 201]. Phosphorus, together with calcium, are fundamental minerals for bone formation. They participate in many biological processes, such as activating enzymes, maintaining acid-base balance, being responsible for the synthesis of nucleic acids or influencing bone mineralisation [Akter *et al.* 2016]. In the skeleton, they are stored in the hydroxyapatite form and are present at 99% and 80% [Proszkowiec and Angel 2013]. Calcium and phosphorus deficiencies further block bone growth, making abnormalities most common [Valable *et al.* 2017]. If these deficits persist over time, they have lasting side effects in the form of rickets, particularly in broilers [Shazly Soheir *et al.* 2021]. Studies of the avian skeleton, i.e. its properties and composition, identify the age (or body weight) of the bird, at which skeletal problems such as tibial dyschondroplasia, femoral fractures or long bone distortions, occur. Therefore, it is believed that morphological and densimetric parameters of the tibia are crucial to gain a closer understanding of the pelvic limb disorders that ducks suffer from [Zhang *et al.*

2019]. These diseases are most often associated with genetic increases in growth [Van Wyhe *et al.* 2012]. In order to better visualise the skeletal structure of birds, various investigative techniques are used, such as X-ray and ultra-sound. These methods allow to see the internal structure of the bone [Charuta and Reymond 2007]. In general, bone resistance to fracture can be reflected in the level of animal welfare [Krunz *et al.* 2022]. Bone problems in ducks are also reflected in meat quality, among other things causing developmental defects in the thoracic muscles, which affects meat texture [Zhang *et al.* 2019]. The available literature lacks information on the digestive traits in Dworka ducks (breeding strain D11) and the metric traits of leg bones (femur and tibia bones) in conservative strain P9 (French Pekin) and breeding strain D11 (Dworka ducks). In the era of the promotion of the free-range housing system, breed assessed ducks are gaining in popularity, and the results obtained furthermore add to the current state of knowledge concerning these duck populations. The aim of this study was to determine the traits of the digestive system and femur and tibia in Dworka and Pekin ducks.

### **Material and methods**

The experiment was conducted with the approval of the Local Ethics Committee for Experiments on Vertebrate Animals in Bydgoszcz, Poland (Resolution no.17/2010 of 23 June 2010).

#### **Carcass collection**

The research material consisted of 24 carcasses of Dworka ducks (breeding strain D11) and 24 carcasses of Pekin ducks from the genetic resources herd (French Pekin, conservative strain P9), with 12 carcasses of males and 12 carcasses of females from each strain. The carcasses were obtained at the age of 113 weeks (after the slaughter of the ducks after two reproductive seasons). The timing for the evaluation of ducks from the P9 (French Pekin) lineage was in accordance with the regulations of the Polish Duck Population Genetic Resources Conservation Program. Male and female ducks of the P9 genetic resources are eliminated after two reproductive seasons. For comparison purposes, carcasses of Dworka ducks from breeding strain D11 were obtained on the same date. During the reproductive season, the ducks from both assessed strains were fed the same diet with the same nutritional value (5.1% crude fat, 4.0% crude fiber, 3.0% calcium and 0.5% phosphorus) and were kept in the same building with similar environment parameters. Depending on the season, the temperature inside the poultry house ranged from 8 (winter period) to 20°C (summer period), while relative humidity ranged from 60 to 70%. The birds had no access to the enclosure during the reproduction period. The length of artificial lighting inside the building in the reproductive season was 14h/d. A commercial complete feed mixture for parent ducks was ground and contained 16.13% CP, 11.09 MJ metabolizable energy. The time of slaughter was related to the liquidation of duck flocks in accordance with the breeding program. Birds originating from the Waterfowl Genetic Resources Station

in Dworzyska (Poland) were slaughtered in a poultry processing plant, according to applicable regulations in the EU and the Polish poultry industry.

#### **Analysis of the carcass, breast and leg muscles, and selected internal organs**

Eviscerated carcasses were chilled in a Hendi chill cabinet (Hendi, Gądkki, Poland) at 4°C for 18 h. Then, the chilled carcasses were individually weighed on electronic balance (Radwag, Radom, Poland) to within 0.1 g. Next, eviscerated carcasses were dissected in accordance with the method developed and described by Ziółecki and Doruchowski [1989]. Gutting included the removal of the gastrointestinal tract and other internal organs (e.g. heart, gizzard, proventriculus, liver, spleen, lungs, pancreas). The following was determined accurate to 0.001 g with an electronic weight Medicat M160: gizzard (without digesta), liver (without gallbladder), heart, and spleen.

#### **Analysis of the digestive system traits and leg bones**

The lengths of the duodenum, jejunum, ileum, both caeca, and the colon were tape measured accurate to 1 mm. The diameters of the respective intestinal sections were measured accurate to 0.01 mm with an electronic calliper. The measurements were made at the beginning, centre and the end part. The average diameters of intestinal sections were determined on the basis of the measurement results. Leg bones separated during dissection were cleaned with hydrogen peroxide (30%), and the morphometric characteristics of the bones were subsequently determined. The following parameters were measured on the femur bone with an electronic calliper accurate to 0.01 mm: greatest length (GL), medial length (ML), greatest breadth of proximal end (GB), greatest depth of proximal end (GD), smallest breadth of the corpus (SM), greatest breadth of the distal end (GC), and greatest depth of the distal end (GE). The following measurements of the tibia were also carried out: greatest length (GL), axial length (AL.), greatest diagonal of the proximal end (GD), smallest breadth of the corpus (SB), greatest breadth of the distal end (SD), and greatest depth of the distal end (DD). Figure 1 shows pictures of the femur and tibia with measurements (a-d). All bone measurements were made following the method by Driesch [1976]. The characteristics of the digestive tract and other important internal organs, as well as leg bones were determined at the Department of Animal Breeding and Nutrition, the University of Science and Technology in Bydgoszcz, Poland.

#### **Statistical analysis**

Averages and the standard error of mean - SEM (collectively for both strains) of the analysed traits were calculated. The computations were performed with the use of the SAS software, ver. 9.4. [2014]. The significance of the differences between the means for the recorded traits was verified by Student's test at  $p < 0.05$ . The correspondence of the empirical distributions for the studied traits to a normal distribution was assessed using the Shapiro-Wilk test. The recorded traits had a normal distribution.

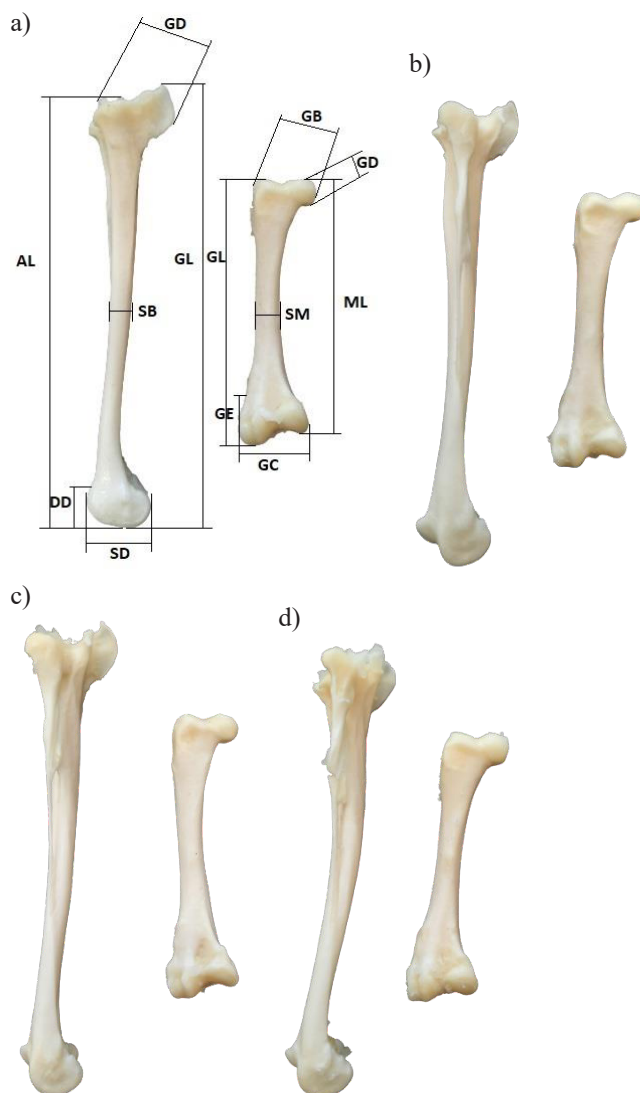


Fig. 1. Tibia and femur bone measurements of Dworka D11 and Pekin P9. a) - male Dworka D11; b) - female Dworka D11; c) - male Pekin P9; d) - female Pekin P9.

## **Results and discussion**

Dworka males and females had statistically significantly heavier eviscerated carcasses; in addition, differences were observed between males and females in Pekin ducks (males were characterised by a heavier eviscerated carcass). The same was

true for the breast muscle, except that additionally statistically significant differences were observed between males and females in the Dworka breed. In the leg muscle, significant differences were observed for the same sex between strains. In the gizzard significant differences were found between Dworka and Pekin females. In terms of liver weight significant differences were observed for each sex between the strains, and in addition, statistically significant differences were recorded between males and females in Pekin ducks. Heart weight was significantly different in females between strains plus between males and females in Pekin ducks. In contrast, spleen weight was significantly different between females and males in Dworka ducks (Tab. 1). In a study by Lewko and Gornowicz [2016] in 10 week-old male Dworka ducks (strain D11), the weight of the eviscerated carcass without giblets was 2059 g, while that of females was 1769 g. In the same study [Lewko and Gornowicz 2016] the breast muscle weight in male and female Dworka ducks was higher (379.9 g in males) or lower (312 g in females) compared to our study. The same was true for the leg muscles in male and female Dworka ducks (246.9 g and 204.9 g). For Pekin P33 ducks of the same age the weight of the eviscerated carcass in males was 1821 g, while that of females was 1599 g. The breast muscle weight in males and females was 314.3 g and 278.6 g, respectively (in our study the results were higher in males and lower in females), while the weight of leg muscles was 213.3 g (males) and 185.8 g (females), i.e. lower in males and females than P9 strain in this experiment. On the other hand, Bernacki et al. [2008] reported that the average weight of the eviscerated carcass in 7-week-old commercial Dworka (CaA15 hybrid) males was 1860 g, while that of females was 1594 g. At the same age, breast muscle weights in male and female Dworka ducks were 259 g and 212 g, respectively, while leg muscle weights were 264 g (males) and

**Table 1.** Weight of the carcass, breast and leg muscles, and selected internal organs in Dworka and Pekin ducks at the age of 113 weeks

Trait		Genotype (G) – sex (S)				SEM	<i>p</i> - values		
		Dworka		Pekin			G	S	GxS
		males	females	males	females				
Eviscerated carcass (g)	mean	2167.2 <sup>a</sup>	2058.0 <sup>a</sup>	1937.0 <sup>b</sup>	1724.6 <sup>b*</sup>	35.8	0.001	0.023	0.358
	sd	179.6	216.2	184.2	188.1				
Breast muscles (g)	mean	361.9 <sup>a</sup>	317.8 <sup>a*</sup>	317.4 <sup>b</sup>	262.1 <sup>b*</sup>	8.3	0.001	0.001	0.678
	sd	32.2	61.8	42.0	44.4				
Leg muscles (g)	mean	238.1 <sup>a</sup>	234.1 <sup>a</sup>	204.9 <sup>b</sup>	192.0 <sup>b</sup>	6.0	0.001	0.488	0.683
	sd	38.7	33.8	49.4	26.4				
Gizzard (g)	mean	90.7	95.7 <sup>a</sup>	87.5	85.5 <sup>b</sup>	2.0	0.096	0.719	0.377
	sd	16.2	7.5	15.1	14.7				
Liver (g)	mean	56.3 <sup>a</sup>	72.8 <sup>a</sup>	43.5 <sup>b</sup>	57.4 <sup>b*</sup>	2.9	0.015	0.008	0.792
	sd	27.5	17.0	6.7	14.3				
Heart (g)	mean	21.0	20.6 <sup>a</sup>	18.7	16.6 <sup>b*</sup>	0.4	0.001	0.144	0.233
	sd	3.0	2.0	2.0	2.6				
Spleen (g)	mean	1.5	2.1 <sup>*</sup>	1.3	1.7	0.1	0.199	0.006	0.619
	sd	0.5	0.7	0.5	0.8				

<sup>a,b</sup>*p*<0.05 – means with different superscripts for the same sex are statistically different between strains.

\**p* < 0.05 – statistical differences between males and females in the strain.

210 g (females). On the other hand, in a study by Kokoszyński *et al.* [2020] a lower weight of male carcasses (1826 g) and a greater weight of female carcasses (1927 g) were obtained from 110-week-old P9 Pekin ducks compared to this study, regardless of genotype, depending on sex. A study by Kokoszyński *et al.* [2019b] showed that the gizzard weight in 49-day-old Pekin ducks (P9 strain) was 66 g, liver weight was 47.5 g, heart weight was 11.4 g and spleen weight was 1.1 g. In terms of sexes, for males the weights were 73.9 g, 45.5 g, 11.0 g, and 1.1 g, whereas for females it was 67.2 g, 41.9 g, 12.2 g and 1.0 g, respectively, i.e. in terms of both genotype and sex in our study the results were higher, which may be due to the different ages of the birds.

For the length of the intestinal segments, statistically significant gender differences for each strain were obtained for the duodenum (additionally, Pekin females had a significantly shorter duodenum compared to Dworka females), jejunum, ileum, total small intestine, total intestine, caeca and colon (in this case, additionally, differences were observed between Dworka and Pekin females). In the case of total intestine, only the differences between Dworka males and females were significant (Tab. 2). In a study by Kokoszyński *et al.* [2019a] in 49-day-old Pekin ducks (P9), the length of the duodenum, jejunum, ileum, caeca and total intestine were smaller than in our study; however, colon length was smaller than in our study. In terms of gender, differences were noted for the jejunum, ileum and caeca. In this study the results were larger; however, the colon was smaller and the duodenum was similar. In a study by Włodarczyk *et al.* [2022] the length of the intestinal segments in 70-week-old Rosa 1 hens and 62-week-old Ross 308 hens differed for the duodenum (in this study among Dworka ducks and in males the results were higher), jejunum (lower values were obtained among Dworka ducks and males in our study), total intestine (lower values were recorded for Rosa 1 among Dworka ducks and males in our study, and lower

**Table 2.** Length of intestinal segments in Dworka and Pekin ducks at 113 weeks of age

Trait	Genotype (G) – sex (S)				SEM	<i>p</i> -values			
	Dworka		Pekin			G	S	GxS	
	males	females	males	females					
Duodenum (cm)	mean	36.2	35.7 <sup>a</sup>	37.4	32.6 <sup>b*</sup>	0.5	0.367	0.006	0.019
	sd	3.1	3.0	3.6	2.4				
Jejunum (cm)	mean	89.0	96.4 <sup>*</sup>	87.4	96.1 <sup>*</sup>	3.2	0.155	0.003	0.102
	sd	15.1	8.4	12.9	15.3				
Ileum (cm)	mean	87.3	94.2 <sup>*</sup>	87.2	92.1 <sup>*</sup>	0.9	0.553	0.001	0.540
	sd	7.4	3.9	5.3	5.3				
Total small intestine (cm)	mean	212.5	226.3 <sup>*</sup>	212.0	220.8 <sup>*</sup>	2.4	0.778	0.002	0.190
	sd	15.4	13.2	15.7	16.7				
Caeca (cm)	mean	39.0	41.6 <sup>*</sup>	37.1	39.8 <sup>*</sup>	0.5	0.049	0.004	0.962
	sd	3.1	2.7	3.0	3.1				
Colon (cm)	mean	9.3	11.9 <sup>a*</sup>	9.7	10.3 <sup>b</sup>	0.4	0.431	0.034	0.154
	sd	3.0	0.7	2.0	1.8				
Total intestine (cm)	mean	260.8	279.8 <sup>*</sup>	258.8	270.9	2.7	0.852	0.001	0.151
	sd	15.8	12.1	16.9	19.7				

<sup>a,b</sup>*p*<0.05 – means with different superscripts for the same sex are statistically different between strains.

\**p*<0.05 – statistical differences between males and females in the strain.

values were obtained for Ross 308 by both genotype and sex in our study). Another study [Wasilewski *et al.* 2015] showed longer total intestine length in 7-week-old Pekin ducks (SM3 Heavy and AF51).

For the percentage of intestinal segments, differences were significant only for the duodenum (between Dworka and Pekin females and between males and females of the same strain) and colon (between Dworka and Pekin females) - Table 3. A study by Wasilewski *et al.* [2015] showed that the percentage length of intestinal segments in 7-week-old Pekin ducks (SM3 Heavy and AF51) was similar to those in our study.

Considering the diameter of the intestinal segments, the differences between Dworka and Pekin females were significant in the case of the jejunum and colon (here the differences were also found between male and female Dworka ducks) (Tab. 4). In a study by Kokoszyński *et al.* [2019a] in 49-day-old Pekin ducks (P9) the diameter of

**Table 3.** Share (%) length of intestinal segments in Dworka and Pekin ducks at 113 weeks of age

Trait		Genotype (G) – sex (S)				SEM	<i>p</i> -values		
		Dworka		Pekin			G	S	GxS
		males	females	males	females				
Duodenum (%)	mean	15.0	12.8 <sup>a*</sup>	14.5	12.0 <sup>b*</sup>	0.2	0.386	0.001	0.113
	sd	1.4	1.0	1.5	1.1				
Jejunum (%)	mean	28.7	34.4	33.7	34.0	1.7	0.671	0.887	0.434
	sd	3.5	2.5	2.4	3.2				
Ileum (%)	mean	36.3	33.8	33.7	34.0	0.3	0.542	0.935	0.310
	sd	4.5	1.0	1.4	2.3				
Total small intestine (%)	mean	79.9	81.0	81.9	81.5	0.2	0.097	0.684	0.905
	sd	1.3	1.3	1.1	1.0				
Caeca (%)	mean	16.2	14.8	14.3	14.7	0.2	0.051	0.887	0.229
	sd	1.7	0.5	0.9	0.5				
Colon (%)	mean	3.9	4.2 <sup>a</sup>	3.8	3.8 <sup>b</sup>	0.2	0.558	0.370	0.156
	sd	1.6	0.9	1.5	0.9				

<sup>a,b</sup>*p*<0.05 – means with different superscripts for the same sex are statistically different between strains.

\**p*<0.05 – statistical differences between males and females in the strain.

**Table 4.** Diameter of intestinal segments in Dworka and Pekin ducks at 113 weeks of age

Trait		Genotype (G) – sex (S)				SEM	<i>p</i> -values		
		Dworka		Pekin			G	S	GxS
		males	females	males	females				
Duodenum (mm)	mean	7.0	7.9	6.9	7.4	0.1	0.481	0.040	0.649
	sd	1.6	0.9	1.6	1.0				
Jejunum (mm)	mean	7.7	7.7 <sup>b</sup>	7.6	8.4 <sup>a</sup>	0.1	0.291	0.197	0.222
	sd	1.1	0.6	1.5	0.7				
Ileum (mm)	mean	8.9	8.9	8.7	9.3	0.2	0.735	0.448	0.501
	sd	1.4	1.4	2.1	0.9				
Caeca (mm)	mean	8.4	8.4	7.2	7.2	0.3	0.022	0.992	0.953
	sd	1.5	1.2	2.4	1.8				
Colon (mm)	mean	10.1	12.0 <sup>a*</sup>	9.8	10.2 <sup>b</sup>	0.3	0.130	0.085	0.232
	sd	2.1	2.0	3.0	1.6				

<sup>a,b</sup>*p*<0.05 – means with different superscripts for the same sex are statistically different between strains.

\**p*<0.05 – statistical differences between males and females in the strain.



all intestinal segments was smaller than in our own study by both genotype and sex. The exception is the diameter of the Rosa 1 segments, in which the ileum, caeca and colon were similar or smaller. The differences in the intestinal diameter and length have an effect on nutrient absorption and the intestinal villus area, which in turn influences productive traits in poultry. The intestinal diameter, as well as length are considerably influenced by the amount of feed intake, species, health, age, gender, body size, breed and physiological status of the birds.

As for significant differences between femur length in the same sex between strains, they were recorded for the greatest length, medial length and greatest breadth of proximal end (only for females). In turn, significant differences between males and females of the same strain were obtained for the greatest length (Dworka), medial length (Dworka and Pekin), greatest depth of proximal end (Dworka), greatest breadth of the distal end (Dworka) and greatest depth of distal end (Pekin) - Table 5. The femurs of birds in terms of their shape resemble those of mammals [Charuta and Reymond 2007]. In 42-day-old broiler chickens Stęczny and Kokoszyński [2020] obtained similar results for the greatest length (GL) of the femur compared to our own study. The results differed for females (irrespective of genotype) and Pekin ducks (irrespective of sex). For ML, GB, GD, SM, GC and GE the results in our study were lower regardless of genotype and sex. In 49-day-old broiler ducks Kokoszyński *et al.* [2019a] showed similar greatest length for Dworka ducks and males from our own study. In contrast, the same authors' study showed greater results for the greatest length in the case of Pekin ducks and females. The same was true for GB, GC and GE. In our own study, greater results were obtained for GD and SM, while they were similar for ML.

**Table 5.** Femur dimensions of Dworka and Pekin ducks at 113 weeks of age

Trait		Genotype (G) – sex (S)				SEM	p - values		
		Dworka		Pekin			G	S	GxS
		males	females	males	females				
GL (mm)	mean	72.4 <sup>a</sup>	70.5 <sup>a*</sup>	69.8 <sup>b</sup>	67.2 <sup>b</sup>	0.4	0.001	0.003	0.594
	sd	1.7	2.0	2.5	1.9				
ML (mm)	mean	68.8 <sup>a</sup>	67.0 <sup>a*</sup>	66.8 <sup>b</sup>	64.0 <sup>b*</sup>	0.4	0.002	0.001	0.575
	sd	2.5	1.8	2.6	1.9				
GB (mm)	mean	16.7	16.9 <sup>a</sup>	16.9	15.6 <sup>b*</sup>	0.2	0.124	0.118	0.019
	sd	0.8	1.3	1.2	0.9				
GD (mm)	mean	12.5	11.1 <sup>*</sup>	11.6	11.7	0.2	0.660	0.055	0.028
	sd	1.6	0.6	0.8	1.3				
SM (mm)	mean	6.8	6.5	6.8	6.7	0.1	0.433	0.236	0.597
	sd	0.6	0.4	0.4	0.6				
GC (mm)	mean	18.1	17.2 <sup>*</sup>	18.0	16.9 <sup>*</sup>	0.2	0.402	0.001	0.725
	sd	1.0	0.6	0.8	0.5				
GE (cm)	mean	9.9	9.8	10.2	9.3 <sup>*</sup>	0.1	0.828	0.052	0.172
	sd	1.3	1.0	0.6	0.5				

GL – greatest length, ML – medial length, GB – greatest breadth of proximal end, GD – greatest depth of proximal end, SM – smallest breadth of the corpus, GC – greatest breadth of the distal end, GE - greatest depth of the distal end.

<sup>a,b</sup>*p*<0.05 – means with different superscripts for the same sex are statistically different between strains.

\* <0.05 – statistical differences between males and females in the strain.

In terms of tibia length, significant differences between the same sex between strains were obtained in greatest length, axial length and between males in smallest breadth of the corpus. In contrast, significant differences between the sexes of the same strain were recorded for the greatest length (Pekin) and axial length (Dworka and Pekin) (Tab. 6). Stępczyński and Kokoszyński [2020] in their study on 42-day-old broiler chickens reported smaller dimensions of GL and AL of the tibia (irrespective of genotype and sex), but larger dimensions of GD, SB, SD and DD (irrespective of

**Table 6.** Dimensions of the tibia in Dworkin and Pekin ducks at 113 weeks of age

Trait		Genotype (G) – sex (S)				SEM	<i>p</i> - values		
		Dworka		Pekin			G	S	GxS
		males	females	males	females				
GL (mm)	mean	123.2 <sup>a</sup>	118.9 <sup>a</sup>	117.5 <sup>b</sup>	113.8 <sup>b*</sup>	0.8	0.001	0.011	0.828
	sd	5.8	4.4	4.4	3.2				
AL (mm)	mean	115.7 <sup>a</sup>	111.7 <sup>a*</sup>	111.6 <sup>b</sup>	106.4 <sup>b*</sup>	0.7	0.001	0.001	0.569
	sd	4.5	2.6	4.0	2.4				
GD (mm)	mean	19.9	19.4	19.4	18.5	0.3	0.222	0.209	0.691
	sd	2.0	1.4	2.2	1.7				
SB (mm)	mean	7.0 <sup>a</sup>	6.5	6.4 <sup>b</sup>	6.2	0.1	0.016	0.126	0.505
	sd	0.9	0.8	0.4	0.4				
SD (mm)	mean	14.5	13.6	13.8	13.4	0.2	0.322	0.323	0.433
	sd	1.5	0.8	0.8	0.6				
DD (mm)	mean	10.7	10.1	10.7	10.1	0.1	0.885	0.031	0.918
	sd	1.1	1.0	0.9	0.9				

GL – greatest length, AL – axial length, GD – greatest diagonal of the proximal end, SB – smallest breadth of the corpus, SD – greatest breadth of the distal end, DD – depth of the distal end.

<sup>a,b</sup>*p*<0.05 – means with different superscripts for the same sex are statistically different between strains.

\**p*<0.05 – statistical differences between males and females in the strain.

genotype and sex). Kokoszyński *et al.* [2019a] in their study on 49-day-old broiler ducks obtained similar dimensions for GL, AL (compared to Dworka ducks and males in their study, while Pekin ducks and females in general had shorter GL and AL) and smaller GD and, SB, while SD and DD were larger compared to our study. Oh *et al.* [2015] showed that dietary and fermented *Chlorella vulgaris* did not affect tibia length; however, it increased tibia resistance.

## Conclusion

In conclusion, the Dworka and Pekin ducks differed in the weight of some internal organs, length and diameter of intestinal segments and dimensions of bones. Differences were also recorded between the sexes of the birds. This may be due, among other things, to different growth rates. In addition, Pekin ducks tend to accumulate fat.

## REFERENCES

1. AKTER M., GRAHAM H., IJI P.A., 2016 - Response of broiler chickens to different levels of calcium, non-phytate phosphorus and phytase. *British Poultry Science* 57, 799-809.

2. BERNACKI Z., KOKOSZYŃSKI D., MALLEK T., 2008 – Evaluation of selected meat traits in seven-week-old duck broilers. *Animal Science Papers and Reports* 26, 165-174.
3. CHARUTA A., REYMOND J., 2007 - Morfologia i morfometria kości obręczy oraz odcinka nasadowego i przejściowego kończyny miednicznej kaczki domowej ((Morphology and morphometry of the pelvic girdle as well as the head and connecting segments in the pelvic limb of the domestic Peking duck). *Medycyna Weterynaryjna* 63, 459-462. In Polish.
4. CHEN X., HU B., HUANG L., CHENG L., LIU H., HU J., HU S., HAN C., HE H., KANG B., XU H., ZHANG R., WANG J., LI L., 2021 - The differences in intestinal growth and microorganisms between male and female ducks. *Poultry Science* 100, 1167-1177.
5. CUI Y-M., WANG J., ZHANG H-J., FENG J., WU S-G., QI G-H., 2019 - Effect of photoperiod on growth performance and quality characteristics of tibia and femur in layer ducks during the pullet phase. *Poultry Science* 98, 1190-1201.
6. COOPER R.G., NARANOWICZ H., MALISZEWSKA E., TENNETT A., HORBANCZUK J.O., 2008 – Sex-based comparison of limb segmentation in ostriches aged 14 months with and without tibiotarsal rotation. *Journal of the South African Veterinary Association* 79, 3, 142-144.
7. DRIESCH A., 1976 - A guide to the measurement of animals bone from archaeological sites. Peabody Museum Bulletin 1. In: Peabody Museum of Archaeology and Ethnology, University of Harvard, 138 pp.
8. DUGGAN B.M., HOCKING P.M., SCHWARZ T., CLEMENTS D.N., 2015 - Differences in hindlimb morphology of ducks and chickens: effects of domestication and selection. *Genetics Selection Evolution* 47, 88.
9. GARRO C., BRUN A., KARASOV W.H., CAVIEDES-VIDAL E., 2018 - Small intestinal epithelial permeability to water-soluble nutrients higher in passerine birds than in rodents. *Journal of Animal Physiology and Animal Nutrition* 102, 1766-1773.
10. KOKOSZYŃSKI D., BERNACKI Z., BIEGNIIEWSKA M., SALEH M., STĘCZNY K., ZWIERZYŃSKI R., KOTOWICZ M., SOBCZAK M., ŻOCHOWSKA-KUJAWSKA J., WASILEWSKI P.D., BUCEK T., KMIECIK M., 2020 - Carcass, physicochemical and sensory characteristics of meat from genetic resource ducks after two reproductive seasons. *South African Journal of Animal Science* 50, 55-68.
11. KOKOSZYŃSKI D., SALEH M., BERNACKI Z., TOPOLIŃSKI T., ANDRYSZCZYK A., WIRWICKI M., 2019a - Growth performance, carcass composition, leg bones and digestive system characteristics in Pekin duck broilers fed a diet diluted with whole wheat grain. *Canadian Journal of Animal Science* 99, 781-791.
12. KOKOSZYŃSKI D., WASILEWSKI R., SALEH M., PIWCZYŃSKI D., ARPAŠOVÁ H., HRNČÁR C., FIK M., 2019b - Growth performance, body measurements, carcass and some internal organs characteristics of Pekin ducks. *Animals* 9, 963.
13. KONARKOWSKI A., 2006 - Rozwój jelita cienkiego u kurcząt (Development of small intestine in chicks). *Polish Poultry* 7, 21-23. In Polish.
14. KRUNT O., KRAUS A., ZITA L., MACHOVÁ K., CHMELÍKOVÁ E., PETRÁSEK S., NOVÁK P., 2022 - The Effect of housing system and gender on relative brain weight, body temperature, hematological traits, and bone quality in Muscovy ducks. *Animals* 12, 370.
15. KSIĄŻKIEWICZ J., 2012 - Rodzime stada zachowawcze kaczek w aspekcie przydatności konsumpcyjnej w kuchniach regionalnych (Conservation Flocks of Native Ducks from the Aspect of Suitability for Consumption in Regional Cuisine). 1st ed. Zespół Wydawnictw i Poligrafii IZ-PIB; Kraków, Poland, pp. 1-44. In Polish.
16. LEWKO L., GORNOWICZ E., 2016 – Porównanie wydajności rzeźnej i mięsnej kaczek różniących się pochodzeniem. (Comparison of the Slaughter and Meat Yield of Ducks of Different Origin). Results of the Evaluation Usability Value of Poultry in 2015; Wiadomości Drobiarskie sp. z o. o: Poznań, Poland, pp. 208-211. In Polish.

17. OH S.T., ZHENG L., KWON H.J., CHOO Y.K., LEE K.W., KANG C.W., AN B.K., 2015 - Effects of dietary fermented *Chlorella vulgaris* (CBT®) on growth performance, relative organ weights, cecal microflora, tibia bone characteristics, and meat qualities in Pekin ducks. *Asian-Australasian Journal of Animal Science* 28, 95-101.
18. PROSZKOWIEC W.M., ANGEL R., 2013 - Calcium and phosphorus metabolism in broilers: Effect of homeostatic mechanism on calcium and phosphorus digestibility. *Journal of Applied Poultry Research* 22, 609-627.
19. ROBISON C.I., RICE M., MAKAGON M.M., KARCHER D.M., 2015 - Duck gait: Relationship to hip angle, bone ash, bone density, and morphology. *Poultry Science* 94, 1060-1067.
20. SAS INSTITUTE INC. (2014). SAS/STAT User's Guide version 9.4. SAS Institute Inc., Cary, NC.
21. SHAZLY SOHEIR A., EL-SHHAT A.M., RAGAB MONA A., MOUSTAFA KOUT ELKLOUB M EL., AWAD A.L., 2021 - Effect of Dietary Calcium and Phosphorus Levels on Productive Performance, Carcass and Tibia Characteristics of Sudani Ducklings. *Journal of Animal and Poultry Production* 12, 131-136.
22. STĘCZNY K., KOKOSZYŃSKI D., 2020 - Effect of probiotic preparations (EM) and sex on morphometric characteristics of the digestive system and leg bones, and caecal microflora in broiler chickens. *Journal of Applied Animal Research* 48, 45-50.
23. VALABLE A.S., NARCY A., DUCLOS M.J., POMAR C., PAGE G., NASIR Z., MAGNIN M., LETOURNEAU-MONTMINY M.P., 2017 - Effects of dietary calcium and phosphorus deficiency and subsequent recovery on broiler chicken growth performance and bone characteristics. *Animals* 12, 1-9.
24. VAN WYHE R.C., APPLGATE T.J., LILBURN M.S., KARCHER D.M., 2012 - A comparison of long bone development in historical and contemporary ducks. *Molecular and Cellular Biology* 91, 2858-2865.
25. WASILEWSKI R., KOKOSZYŃSKI D., MIECZKOWSKA A., BERNACKI Z., GÓRSKA A., 2015 - Structure of the digestive system of ducks depending on sex and genetic background. *Acta Veterinaria Brno* 84, 153-158.
26. WATKINS E., BUTLER P., KENYON B., 2004 - Posthatch growth of the digestive system in wild and domesticated ducks. *British Poultry Science* 45, 331-341.
27. WEN M., WU B., ZHAO H., LIU G., CHEN X., TIAN G., CAI J., JIA G., 2019 - Effects of dietary zinc on carcass traits, meat quality, antioxidant status, and tissue zinc accumulation of Pekin ducks. *Biological Trace Element Research* 190, 187-196.
28. WŁODARCZYK K., KOKOSZYŃSKI D., SALEH M., PIWCZYŃSKI D., 2022 - Carcass characteristics, digestive system traits of spent broiler breeder and dual purpose hens. *Animals* 12, 1320.
29. ZHANG Y.N., WANG S., LI K.C., RUAN D., CHEN W., XIA W.G., WANG S.L., ABOUELEZZ K.F.M., ZHENG C.T., 2020 - Estimation of dietary zinc requirement for laying duck breeders: effects on productive and reproductive performance, egg quality, tibial characteristics, plasma biochemical and antioxidant indices, and zinc deposition. *Poultry Science* 99, 454-462.
30. ZHANG H.Y., ZENG Q.F., BAI S.P., WANG J.P., DING X.M., XUAN Y., SU Z.W., FRALEY G.S., ZHANG K.Y., 2019 - Study on the morphology and mineralization of the tibia in meat ducks from 1 to 56 d. *Poultry Science* 98, 3355-3364.
31. ZIOŁECKI J., DORUCHOWSKI W., 1989 - Evaluation Methods of Poultry Slaughter Values, 1st ed.; Poultry Research Center: Poznań, Poland, pp. 1-23.